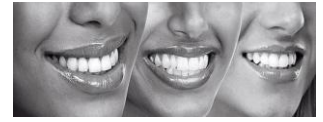



# The Hub Dental Practice



## Looking Nicer By Gul

### Introduction

The Hub Dental Practice is delighted to welcome Gulelala, who completed her Post Graduate Degree at the world renowned Centre of Excellence" at The University of Sheffield Postgraduate Dental School.

She is an International speaker and was working as an Assistant professor at the Riphah University in Pakistan, delivering lectures and carrying out hands-on workshops on Cosmetic Dentistry all over the Country.

Gulelala also works at the Hub Dental Practice. Gul offers weekday and weekend appointments. She works closely with Jaime, George and Ezgi who place our implants, to ensure that our patients get the best possible results.

She has carried out extensive work in Cosmetic and Restorative dentistry over the past 6 years. And has worked extensively with Cerec Cad-Cam Machine, milling the crowns/Veneers for the patients and Staining and glazing them in the Furnace to give life like appearance to them.

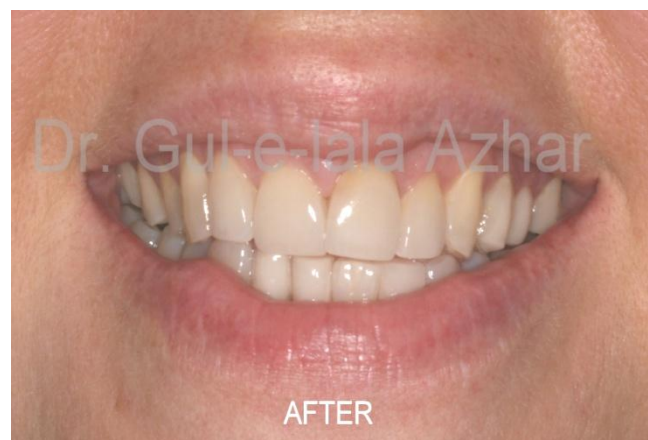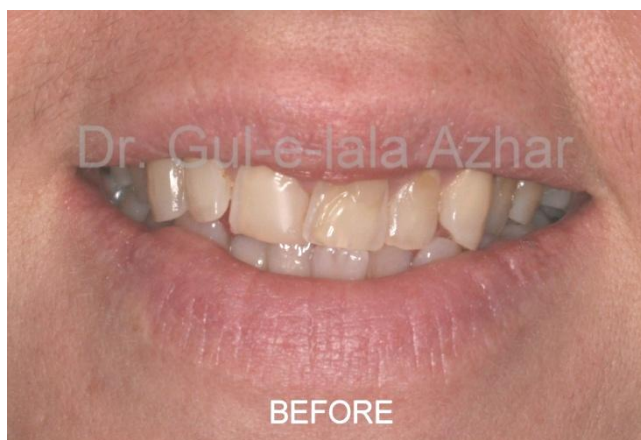One of the reasons why Gulelala chose to work at our practice was because we have the latest Cerec Technology as well as the fact that we are about to get our own 3D CT Xray Scanner.

As Exclusive Private Dental Practices in Milton Keynes Cambridge we are determined to stay at the top. We know that constant investments in new tecknowlegy, ongoing Post Graduate Training as well as using only the best materials is the only way to maintain our highest standards.

### Case 1

#### From an un-even smile to a nice straighter smile

This patient here wanted to brighten and straighten her teeth and she did not want any extensive work such as crowns. Her smile was improved by providing her with Porcelain Veneers on 4 upper teeth and aesthetic composite build ups on lower teeth and some upper left teeth to give the patient a straighter brighter smile.



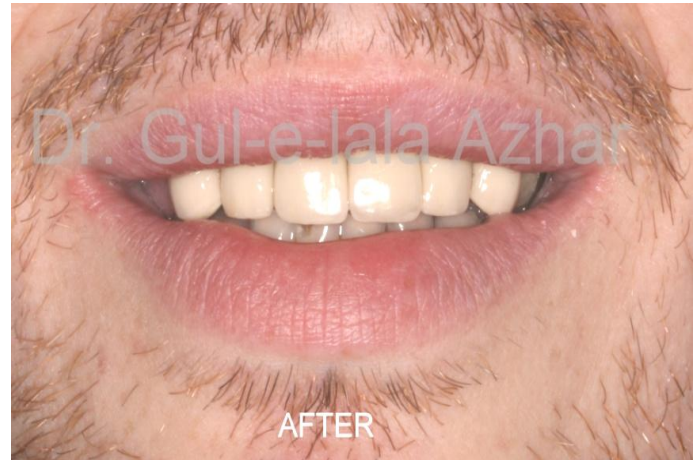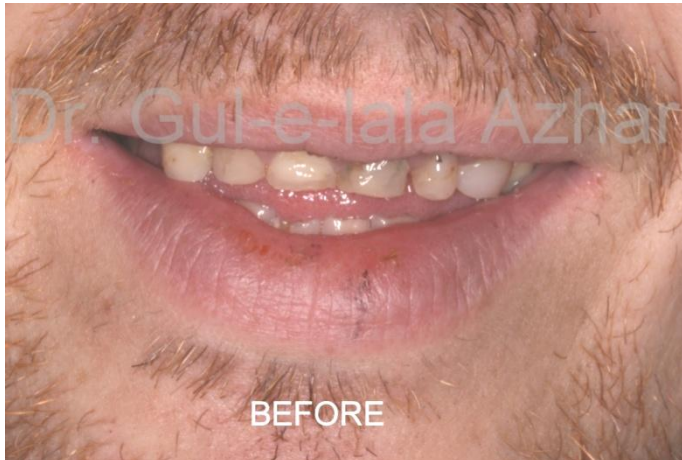## Case 2

### From small teeth and unsightly smile to a nice and bright natural smile

This patient here wanted to improve his smile and only wanted work done on his front teeth.

His smile was improved by restoring his upper front teeth with six porcelain fused to metal crowns.

He was extremely happy with the results and later on wanted to get his back missing teeth replaced too.



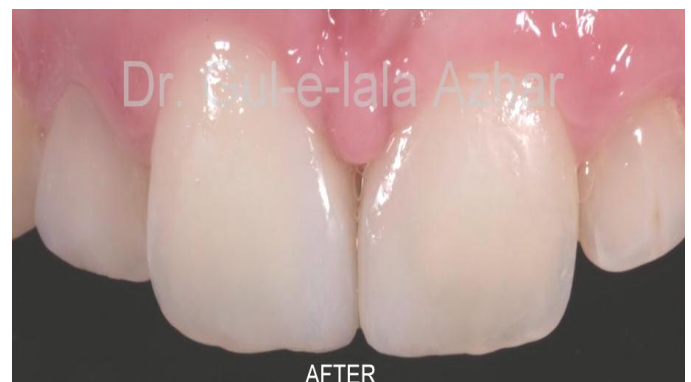
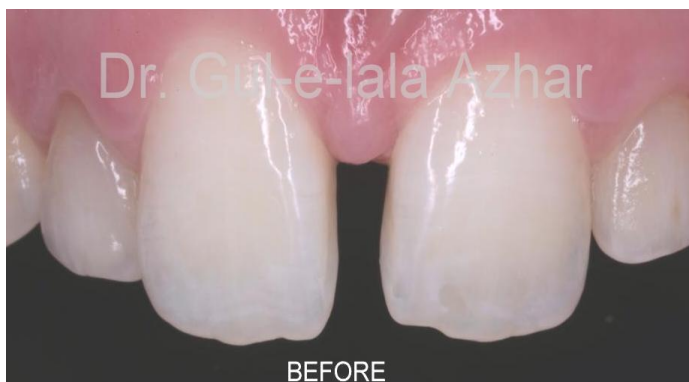## Case 3

### I hate that gap to wow I love my teeth

This patient here wanted the space closed between her upper central front teeth.

She did not want any expensive treatments such as Veneers/crowns or even refused the Orthodontic treatment.

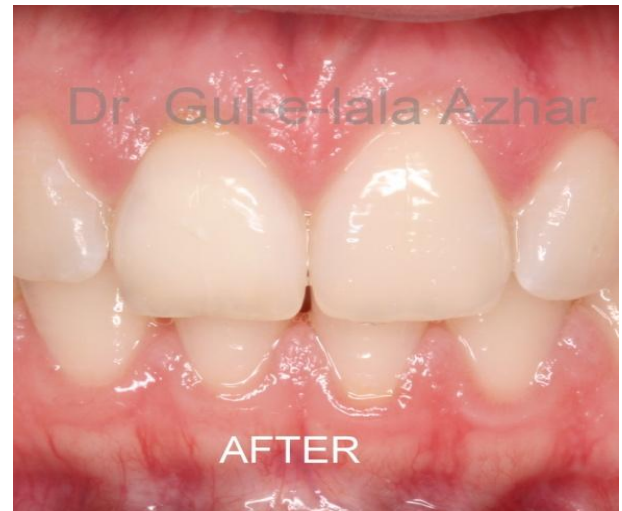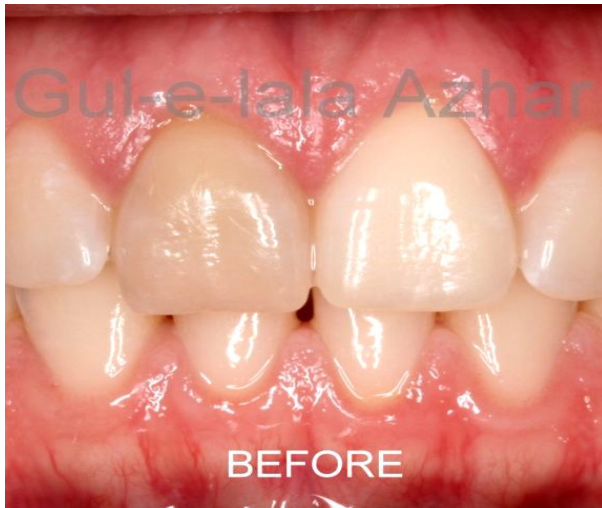The space was closed by simply using a tooth coloured filling materials and building up the two central teeth to close the gap.



## Case 4

### from a discoloured ugly prominent tooth to nicely blended white teeth

This patient had a history of child hood trauma on one of her front teeth. Internal bleaching was done for her after carrying out RCT on that tooth. Internal bleaching can be done for teeth that discolour over time following a trauma. A bleaching agent is placed inside the tooth over a period of 2 to 3 weeks and gives brilliant results.



## Case 5

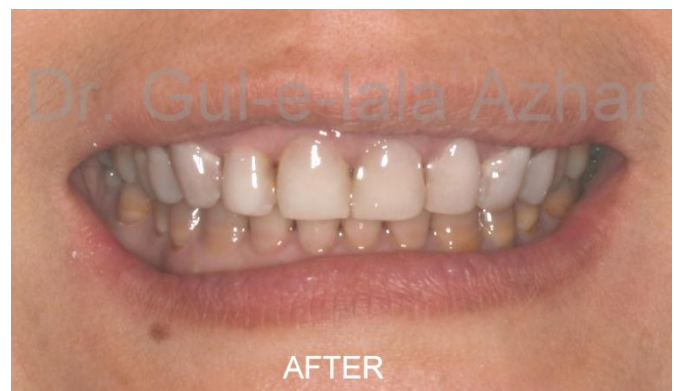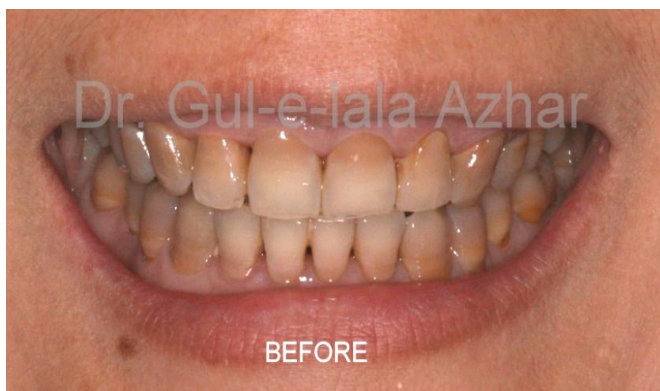### No preparation tooth coloured filling material to hide the yellow/brown tetracycline bands.

This patient below had type 2 Tetracycline stains.

Teeth whitening was first attempted as she did not want any invasive treatments, but due to her non-compliance to the whitening trays and bleaching agent, the whitening treatment was abandoned.

It was decided to just provide her with a tooth coloured filling material on all her upper teeth without taking or grinding any tooth structure off.

A very white and opaque filling material (Composite) was used to provide her with these Componeers on all her upper teeth without any preparation of the teeth.





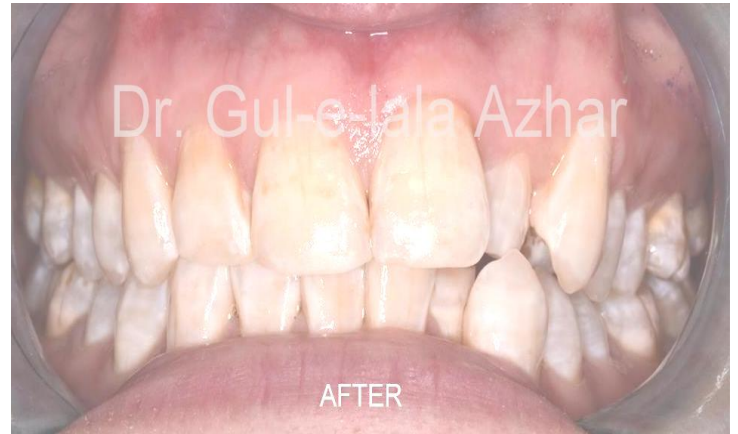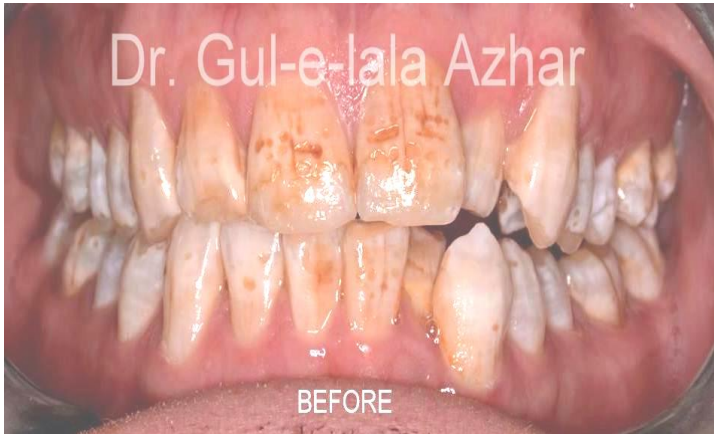## Case 6

I love my teeth. they don't look brown and ugly anymore. NO DRILLING!!!

This patient presented with flourosis and dis-colouration on all his teeth. Initial treatment planning involved micro-abrasion followed by teeth whitening and porcelain veneers if there is no improvement.

After two visits of micro-abrasion (which involves polishing the teeth with a paste made of coarse sand and a mild acid) under a rubber dam to protect the gums and lips, and a single visit of teeth whitening the following results could be seen.

Patient was very happy.



## Case 7

From bulky veneers and a deviated smile to natural looking veneers and even smile

This pleasant lady already had veneers which she got some ten years ago. She felt that they were too bulky and she felt that rightly so. She also did not like the way it made her smile look uneven.

The midline of her upper lip did not coincide with the midline of her teeth.

A new set of veneers were provided to her which were much thinner than her old ones and looked much more natural and her smile looked symmetrical not just to her but to us too.

